

98% SUCCESS OF **MODE** **IMPLANT** SYSTEM

Since 2012 I am using Mode Medical Products in my clinic. I applied up to 1500 Mode Implants my patients. I am trying to file and follow my cases meticulously. I am very satisfied with the results of 5 years follow-up cases with up to %98 success rate.

CASE 1
AGE:54
SEX:MALE
Systemic disease: non

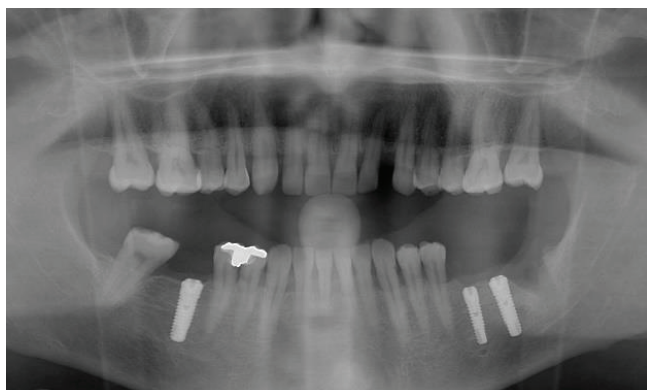


FIGURE 1: Post-op

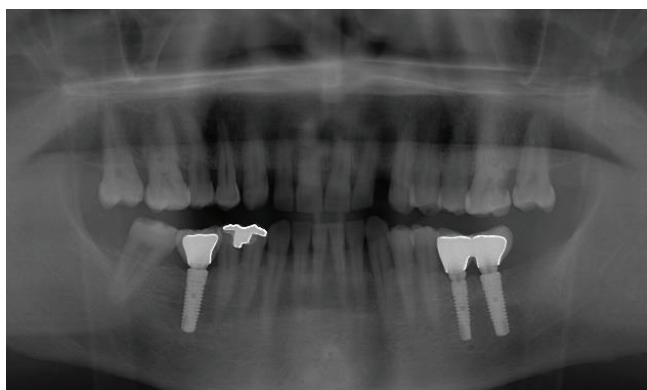


FIGURE 2: 5th year control

CASE 2
AGE:59 SEX:MALE Systemic disease: Diabetes

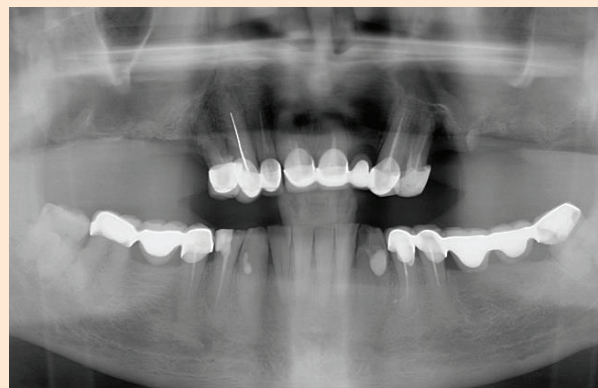


FIGURE 1:
Pre-op

CASE 3
AGE:47
SEX:MALE
Systemic disease: non

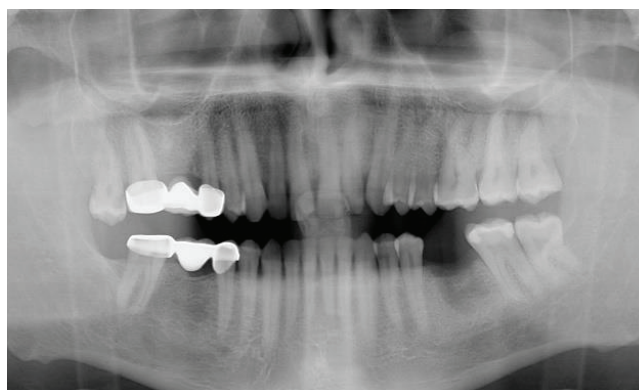


FIGURE 1: Pre-op

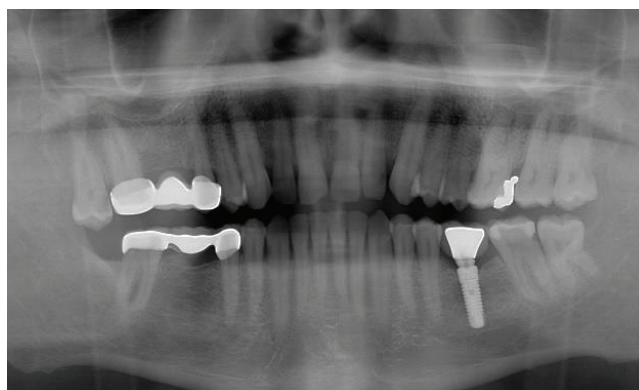


FIGURE 2: 5th year control

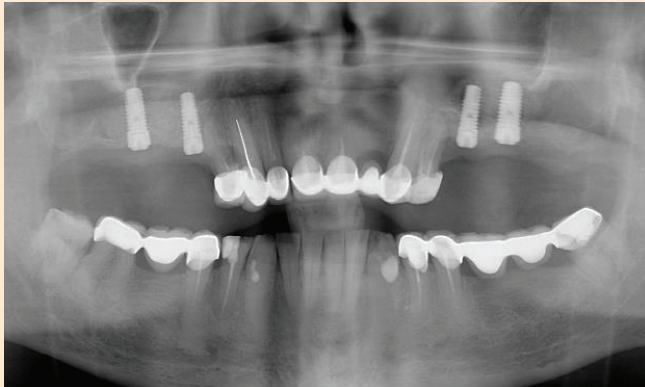


FIGURE 1:
Post-op

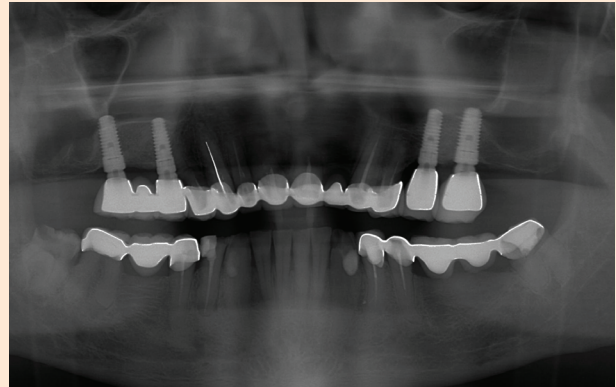


FIGURE 2:
5th year control

CASE 4
AGE:75
SEX:MALE
Systemic disease: Hypertension

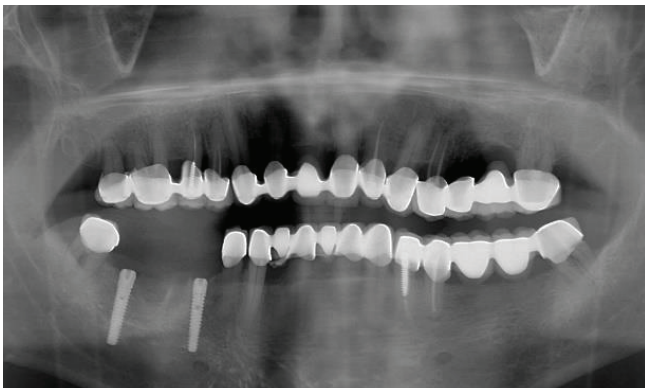


FIGURE 1: Post-op

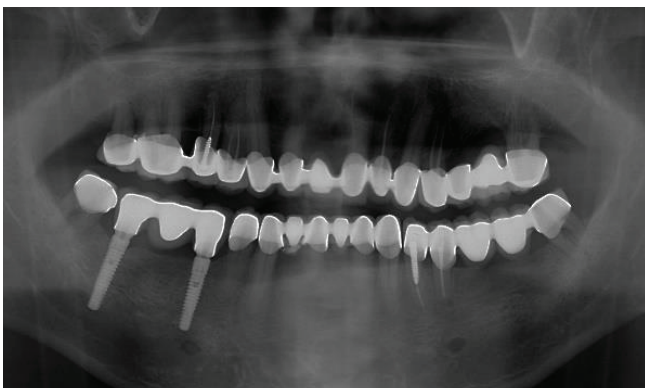




FIGURE 2: 5th year control



Dr. A. Selhan Kaya

ORAL AND MAXIOFACIAL SURGEON

He graduated from Istanbul University Faculty of Dentistry in 2005. At the same year, he started his doctorate education in the field of oral and maxillofacial surgery in Istanbul University. Between 2005-2010 he carried on his academic and clinical studies in Istanbul University Faculty of Dentistry. He successfully completed his thesis study on surface characteristics of dental implants and he is entitled as Oral and Maxillofacial Surgeon. He is a member of various charities and professional associations. He is a board member of Turkish Dental Chamber of Antalya since 2012 and also General Secretary of 16th term. He is also a delegate of Turkish Dental Association. He continues his studies in Asklinik Oral and Dental Health Clinic in Antalya since April 2011.



Dr. Ülkem Cural

ORAL MAXILLOFACIAL SURGERY DDS, PHD

22 years old male patient referred to our clinic with fossa canine abscess. After clinic and radiographic examination cystic lesion detected at the right incisor area. Cyst enucleated immediately but unfortunately the related teeth had to be extracted. The pathologic investigation resulted as radicular cyst. After healing prosthetic rehabilitation discussed. The decision was implant supported fixed prosthesis. but the residual bone was insufficient. The vestibular bone Wall was vanished and there was a dehiscence defect at the palatal Wall. 3D bone augmentation with mandibular ramus bone block graft was planned. 4 months after fist surgery implants were placed. Waited for 3 months for osteointegration and final prosthesis applied.

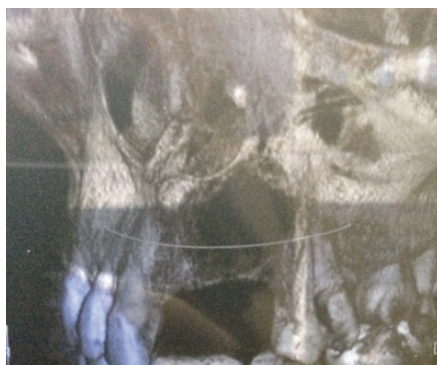

Photo 1: Bone defect after cyst enucleation

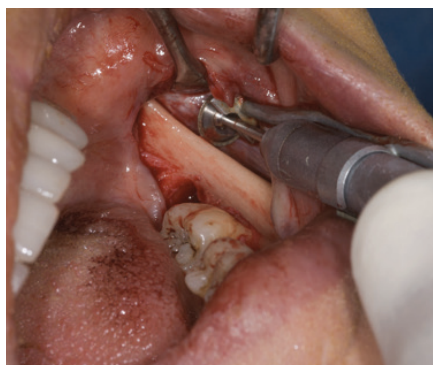

Photo 2: Harvesting bone block from ramus of mandibula

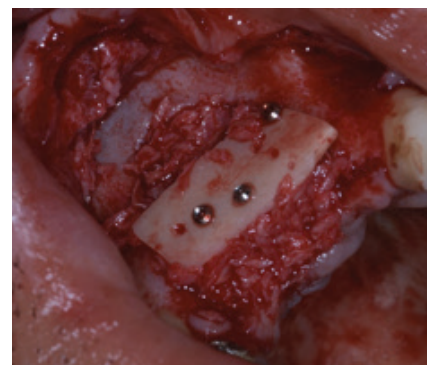


Photo3 : Augmented defect area

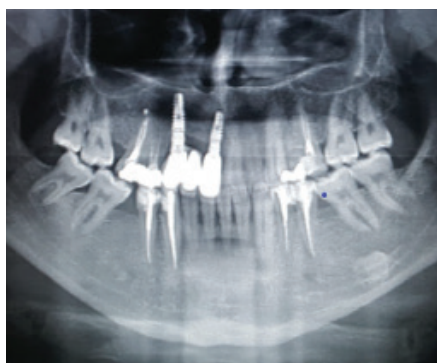

Photo 4: Radiography of implants with prosthetic rehabilitation

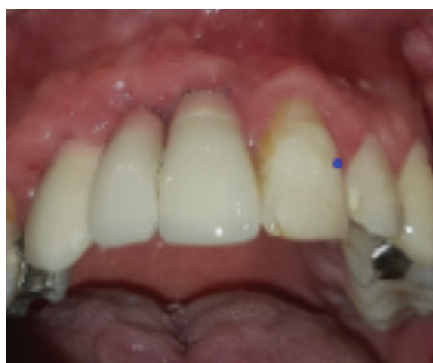

Photo 5: Final intra oral view



Dr. Uğur Mercan

ORAL AND MAXILOFACIAL SURGEON

60 years old male patient was referred to our oral and maxillofacial surgery department about complaining of dental infection in the left posterior region of the maxilla. He was a diabetic patient and his HbA1c level was 11.2 (mmol/mol). Patient was consulted to endocrinology department after the endocrinology treatment HbA1c level were increased and infected teeth were extracted under the prophylaxis antibiotics protocol. After 3 months the patient's HbA1c level was decreased to the 7.1 (mmol/mol) and the implant treatment was decided. We planned to place implant with sinus lift at the same surgery. A-PRF and I-PRF were applied to sinuslift according to the Choukroun protocol. 2 MODE implants (3.7x11.5, 4.7x8mm) were placed to the maxillar left molar area. 6 month later implant crown was placed by prosthodontist. After 2 years followed up, a periapical radiograph was taken to check bone level of implant. According to the clinical and radiographic examination results, there was no bone resorption around MODE dental implants

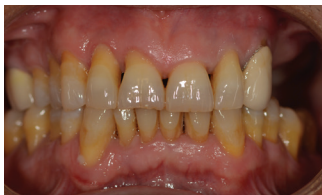

Figure 1. intraoral view of pre surgery

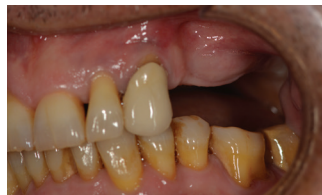

Figure 2. Lateral view of teeth absence in posterior maxilla.

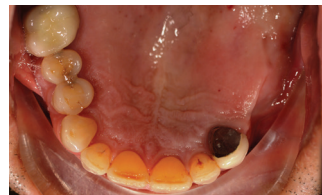

Figure 3. Intraoral occlusal view.

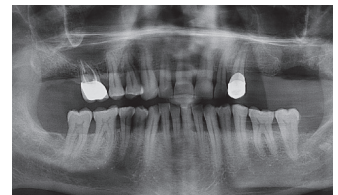


Figure 4. Panoramic view of pre surgery

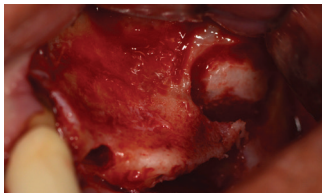


Figure 5. Opened bone window for sinus lift.

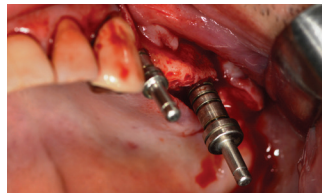


Figure 6. Preparation of implant site.

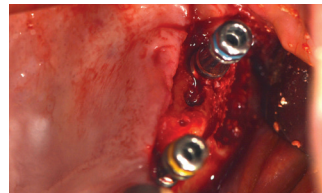


Figure 7. Placed 2 Mode dental implants.

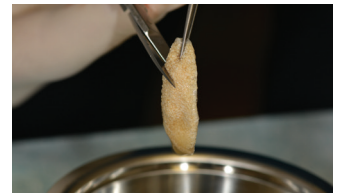


Figure 8. I-PRF was applied to the bone graft

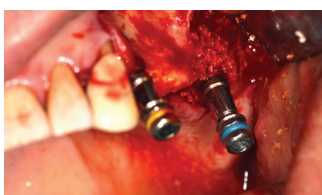

Figure 9. Placed Mode dental implants.

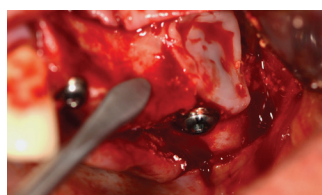


Figure 10. A-PRF and I-PRF were applied to sinuslift area.

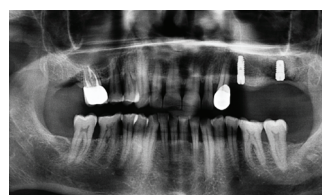


Figure 11. Panoramic view of post surgery.

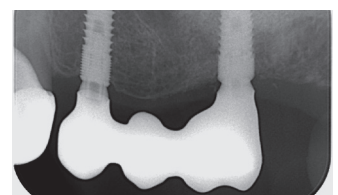


Figure 12. Periapical radiograph view of 2 years followed up.